

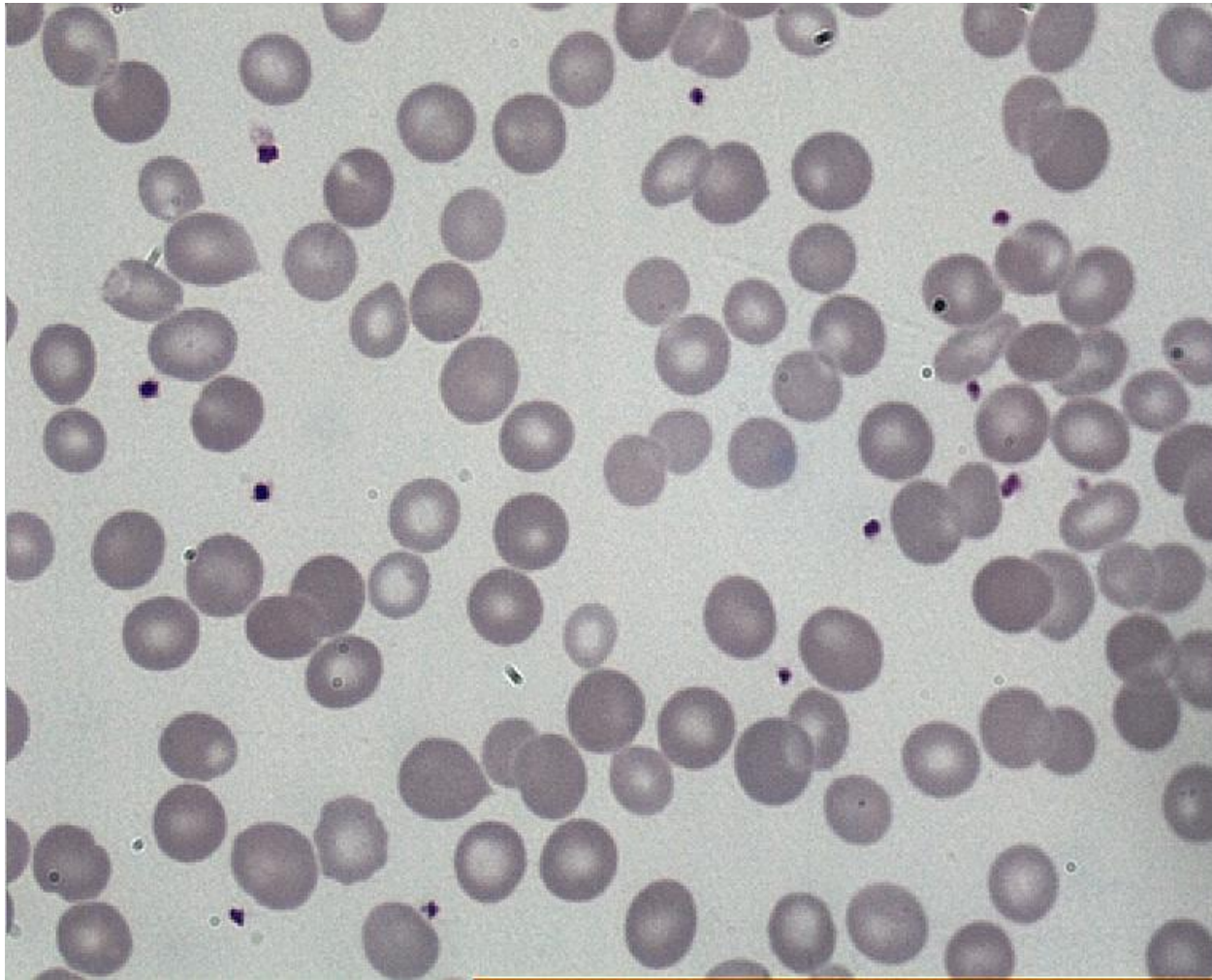
# **CASE DISCUSSIONS IN HAEMATOPATHOLOGY**

**K Gayathri**

**IAPP.Pune.May4th 2014**

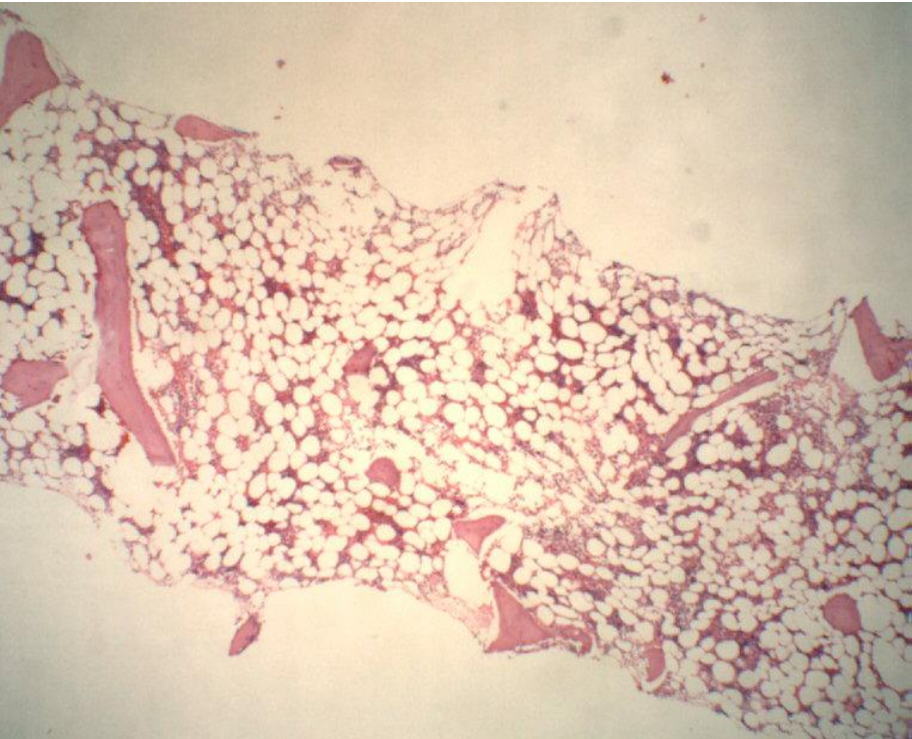

## Case: 1

Infant 4 months, with progressive anemia and jaundice.  
Received Blood Transfusion from mother (70ml) at 7 days age  
for Hb 7.5g/ dl.



**Case: 2**

Girl 12 years, detected with transfusion dependant anemia since the age of 4 years. On examination short and small or age; no lymphadenopathy or organomegaly.

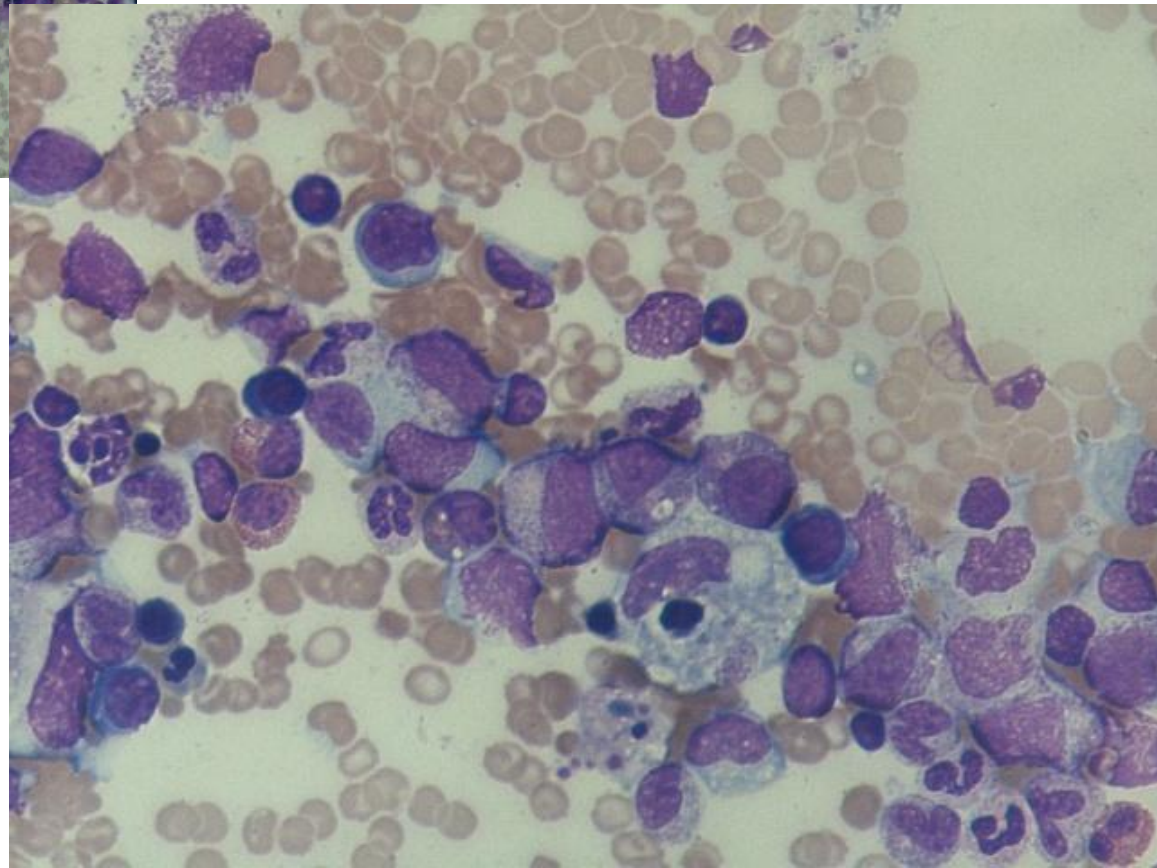
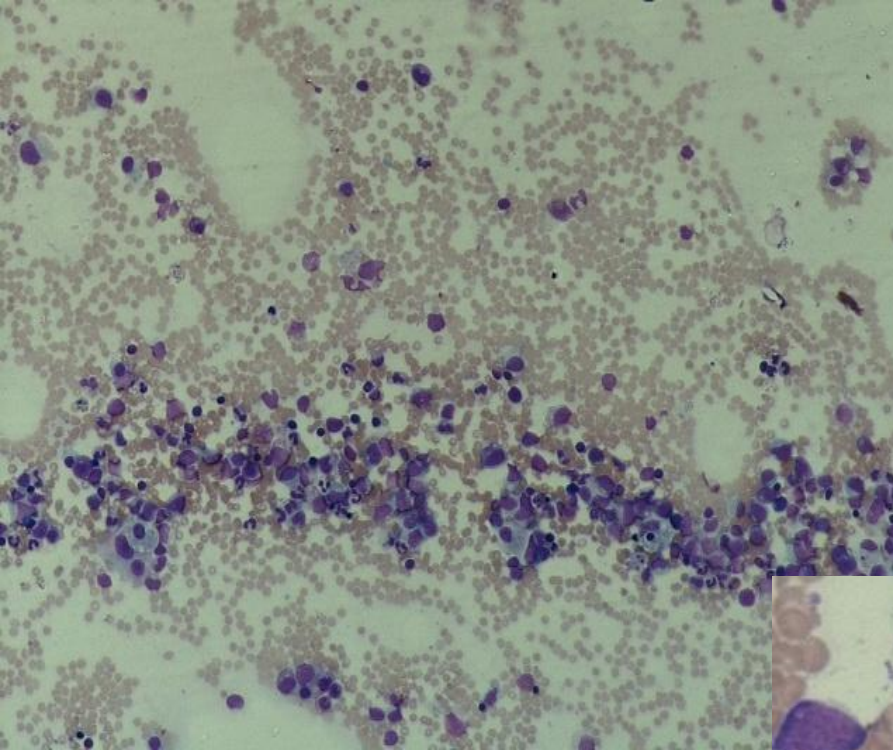




### Case: 3

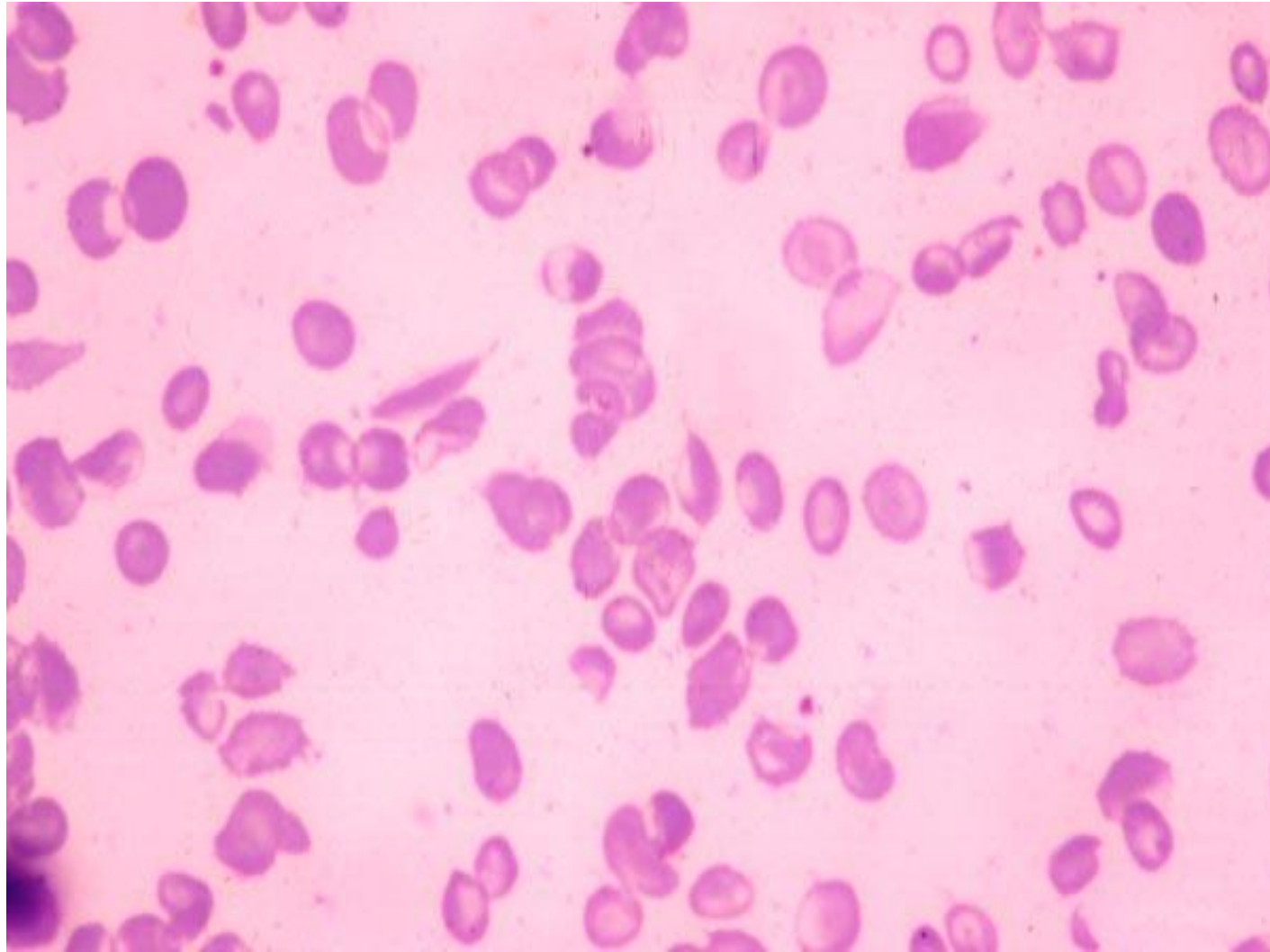
Girl 9 years, admitted with intermittent fever of 1 year.

On examination with pallor and mild icterus; hepatosplenomegaly. Hb 4.7g/dl; TLC 2300/ cumm; Platelets 20000/ cumm.



**Case: 4**

Boy 8 years, with joint pains, fever.  
On examination small built, pale with mild  
icterus



## Case: 5

Boy 5 years, with complaint of passing blood in urine since day prior to presentation. Also yellow eyes since then, with pain abdomen and vomiting. Had similar episode at age 3 and received blood transfusion. Remained well between these episodes

